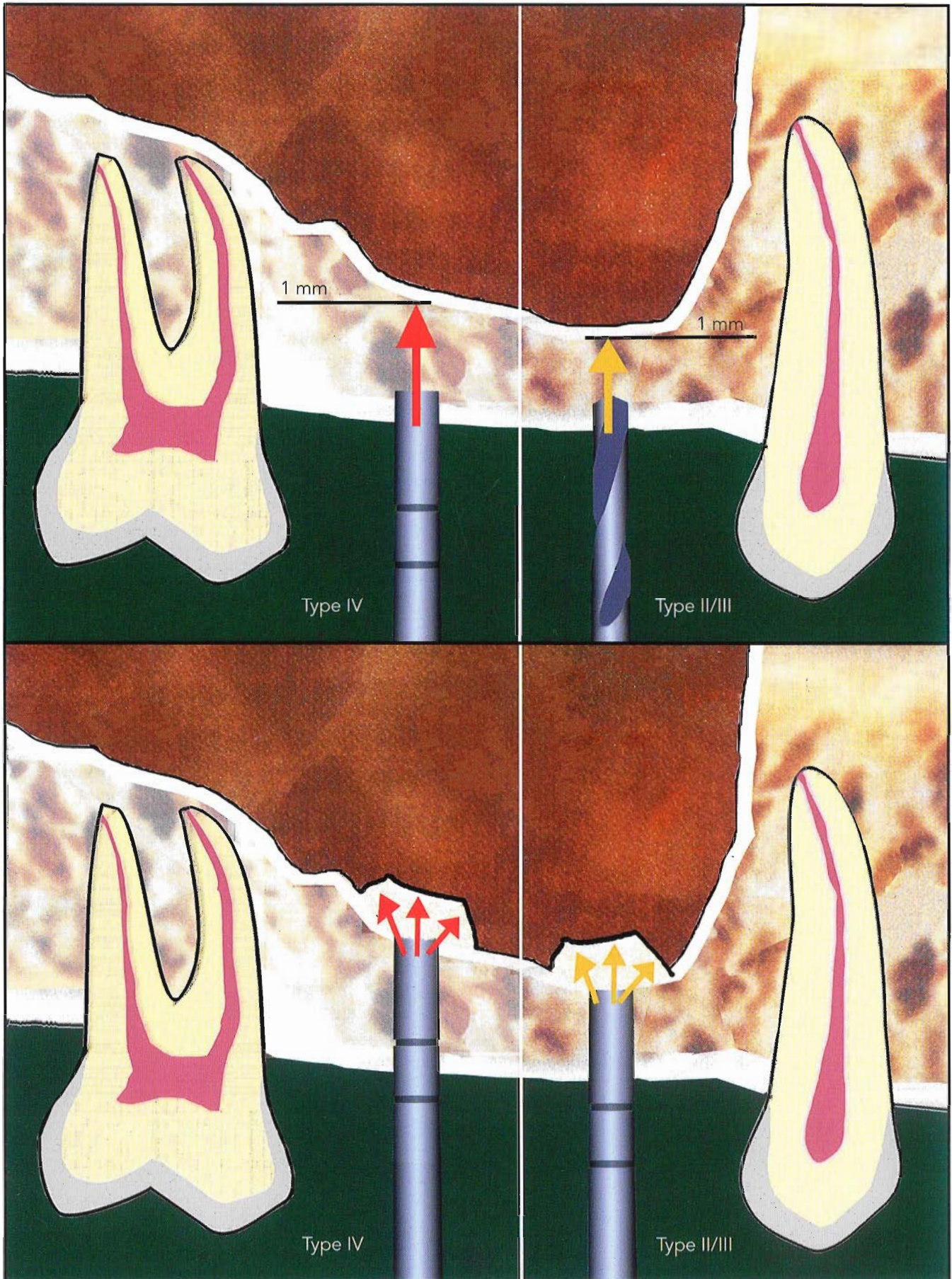
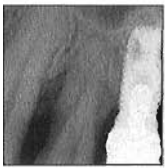
Simplified Osteotome Sinus Augmentation Technique with Simultaneous Implant Placement: A Clinical Study



Nicola Marco Sforza, DDS*
 Matteo Marzadori, DDS**
 Giovanni Zucchelli, DDS, PhD***

The aim of this study was to describe and evaluate a modified maxillary sinus floor augmentation technique: the simplified osteotome technique. The study consisted of 26 patients treated with 39 Brånemark implants (Nobel Biocare) placed using the simplified osteotome technique between September 1997 and November 2004 (87 months). Implant length ranged from 10 to 15 mm, while the loading time ranged from 5 to 74 months (mean: 35.2 months). The success rate was 97.4% according to Albrektsson's criteria. These preliminary data indicate that the simplified osteotome technique is effective and safe, though long-term, multi-center studies are still needed. (Int J Periodontics Restorative Dent 2008;28:291-299.)

*Private Practice, Bologna, Italy.

**Intern, Department of Oral Science, Bologna University, Bologna, Italy.

***Associate Professor, Department of Oral Science, Bologna University, Bologna, Italy.

Correspondence to: Dr Nicola Marco Sforza, p.zza Aldrovandi 12, Bologna, Italy; e-mail: nsforza@studiosforza.net.

Proper implant therapy is influenced by the anatomic and structural characteristics of the supporting bone. In particular, the bone quality and quantity are critical factors of clinical success.¹⁻⁴ The maxilla often presents types III or IV bone quality (according to Lekholm and Zarb's classification of 1985⁵). Bone quantity is influenced by the degree of resorption of the alveolar crest and by the dimensions of the maxillary sinus⁶⁻⁸; both factors may represent an obstacle to primary stability of the implant. For these reasons, surgical techniques aimed at augmenting bone quantity⁹ and improving bone quality have been established.¹⁰⁻²²

In 1994, Summers¹⁰⁻¹³ introduced osteotome sinus floor elevation, which is a minimally invasive technique that allows for localized maxillary sinus elevation in alveolar crests with a residual height between 5 and 10 mm. To carry out this technique, it is necessary to use manual instruments—Summers' osteotomes—that apically and laterally compress the bone at the implant site. Summers' study of 55 patients and 143 implants resulted in a success rate of 96%, determined on the basis of the following criteria: loss of bone support

Table 1 Success rates of different osteotome sinus lift techniques in the literature

Study	Vertical dimension (mm)	No. of patients	No. of implants	Implant length (mm)	Implant type	Loading time (mean)	Observation period (mo)	Success
Summers ¹⁰⁻¹³	5-10	55	143 (78% posterior maxilla)	8-16	NA	11-27 mo (18)	NA	96%
Bruschi ¹⁴	5-7	303	499	NA	IMZ, Frialit-2	24 mo to 5 y	69	97.5%*
Fugazzotto ²³	NA	NA	101	> 10	Straumann	NA	NA	100%*
Deporter ¹⁵	> 3	16	26	≤ 7	Endopore	6-36 mo (11.1)	NA	100%
Cosci and Luccioli ²⁴	2-10	237	265	13-15	Integral, Sulzer- Calcitek, hydroxyapatite-coated	NA	NA	8 failures
Cavicchia ¹⁹	≥ 5	NA	97	8-15	NA	6-90 mo (35)	NA	88.6%*
Cordioli ¹⁷	4-7	30	46	10-13	Osseotite	8-? mo (22)	18	95.7%*
Fugazzotto ¹⁶	4-5	61	51	NA	Straumann	NA	NA	100%*
Toffler ²¹	3-10	167	276	8.5-15	3i/Implant Innovations, Osseotite, Astra Tech ST, Frialit-2, Dentsply/Friident	1-84 mo (27.9)	90	93.5%†

*Albrektsson's criteria.
†Survival.

of less than 2 mm and lack of mobility in the bimanual test. To augment the elevation procedure, the author described a variation of the osteotome sinus floor elevation technique: the bone-added osteotome sinus floor elevation technique, which introduced the use of graft material. Subsequently, other authors¹⁴⁻²⁴ suggested a series of changes to Summers' original technique in terms of the implant surface, instruments, and/or surgical protocol.

In particular, Davarpanah et al¹⁸ and Deporter et al¹⁵ suggested the use of rough or porous-surfaced implants to increase primary stability when placing implants in crests with a residual vertical dimension of less than 5 mm (Table 1).

In a longitudinal study consisting of 303 patients and 499 implants, Bruschi et al¹⁴ suggested using different instruments from Summers' osteotomes for the preparation of implant sites, and reported a success rate of 97.5%. Fugazzotto¹⁶ described a two-stage technique using trephine drills combined with osteotomes, achieving a success rate of 100%. On the other hand, Davarpanah et al¹⁸ and Cavicchia et al¹⁹ recommended implant site preparation using either osteotomes and a rotating instrument with helical drills or only the latter. In a longitudinal study of 167 patients and 276 surgical sites, Toffler²¹ proposed the use of modified osteotomes, with a survival rate of 93.5%. Furthermore,

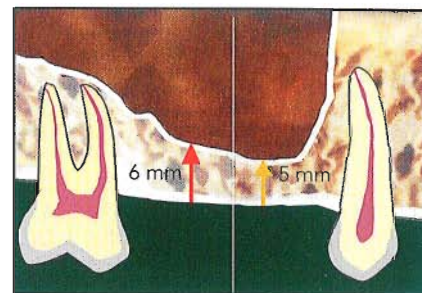
Bruschi et al,¹⁴ Cavicchia et al,¹⁹ and Nkenke et al²⁰ suggested that the sinus floor fracture should be induced without using shock absorber material between the osteotome and bone cortex (Table 1). Finally, Cordioli¹⁷ and Nkenke et al²⁰ introduced the use of instruments for videoradiography and sinuscopy to monitor every stage of the surgical procedure.

The aim of this paper is (1) to present a step-by-step description of a minimally invasive modified maxillary sinus augmentation procedure, the simplified osteotome technique; and (2) to assess the success rate of implants placed simultaneously with this technique.

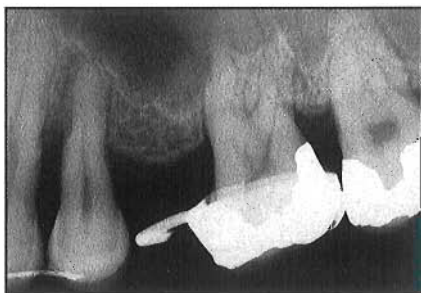

Fig 1 Preoperative intraoral radiograph.

Fig 2 The vertical bone dimension at the implant site (between the sinus floor and bone crest) must measure at least 5 mm.



Method and materials

From September 1997 to November 2004, 26 patients (2 men and 24 women; average age: 47.7 years) were treated consecutively by the same specialist in implant therapy. Thirty-nine Brånemark implants (Nobel Biocare) were placed using the simplified osteotome technique. The primary inclusion criterion was the presence of vertical bone quantity in the implant site (between the sinus floor and bone crest) of no less than 5 mm (Figs 1 and 2). Written informed consent was obtained from all patients.

Presurgical evaluation

The exclusion criteria were as follows: uncontrolled diabetes and immunodepression, chemotherapy or radiotherapy to the head and neck during the last 12 months, uncontrolled periodontal disease or refusal to undergo any periodontal therapy before surgery, current or frequent sinusitis, cigarette smoking (15 or more cigarettes per day), psychologic conditions such as depression or anxiety, and

refusal to undergo any supporting periodontal therapy.

Intraoral radiographs were taken of the implant site using the parallel technique (Fig 1), and orthopantomograms were analyzed if already available. In particularly complex cases, or if there were doubts about the thickness of the alveolar crest, computerized tomography was carried out (eight cases). Intraoral radiographs were taken again after 6, 9, and 12 months postsurgery, and then annually thereafter. All implants were assessed on the basis of Albrektsson's criteria.

Surgical technique

All patients were treated with a nonsteroidal anti-inflammatory drug (Aulin 100 mg, Roche), antibiotic (Amoxicilline EG 2 g), and a bland sedative (Valpinax 20 mg, Crinos) 1 hour before surgery. After administration of local anesthesia with lidocaine (Eccocaine 20 mg, Molteni Dental) 1:50,000, a full-thickness crestal flap was raised, with releasing incisions if necessary. The sinus floor augmentation technique was performed as follows:

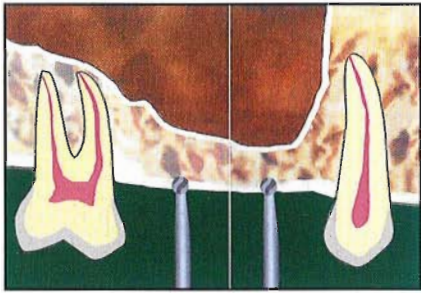


Fig 3 (left) A 2-mm round drill is used to penetrate the bone cortex.

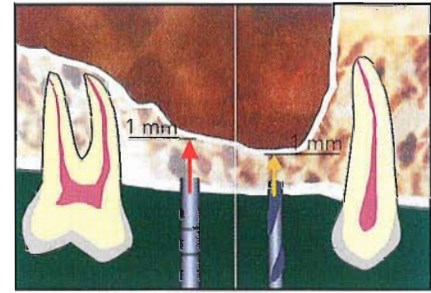


Fig 4 (right) The working depth is 1 mm coronal to the sinus floor.

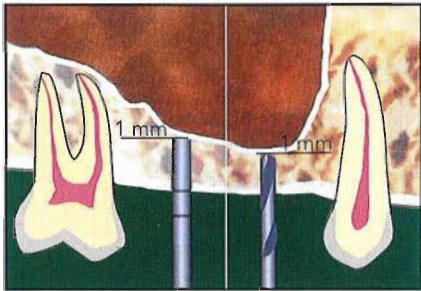


Fig 5 (left) The initial preparation of the implant site is carried out with osteotomes in type IV bone and helical drills in type III bone.

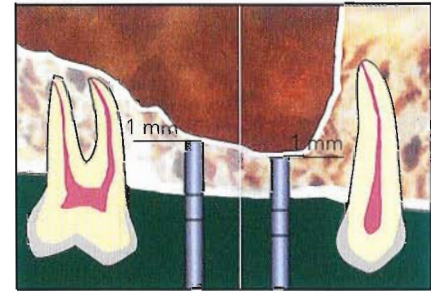


Fig 6 (right) The preparation of the implant site is completed with osteotomes at the working depth.

1. *Socket execution:* A round drill with a diameter of 2 mm was used (Fig 3). After the superficial layer of the bone site was perforated, it was possible to test the medullar density and record the bone quality.⁵
2. *Implant site preparation:* Two different procedures—based on the bone quality—were adopted to maintain a working depth of 1 mm coronal to the sinus floor (Fig 4):
 - In the presence of type II or III alveolar bone, the implant site was initially prepared using spiral drills with a diameter of 2 mm (Fig 5).
 - In the presence of type IV alveolar bone, the implant site was prepared using Summers' osteotomes exclusively with increasing diameter (Fig 5).

- In all cases, the preparation was completed with osteotomes (Fig 6). The diameter of the instruments used was based on the diameter of the implants used: 3-mm instruments were used for 5-mm implants, while 2-mm instruments were used for 4-mm implants. This underpreparation guaranteed excellent primary stability for all implants.
3. *Bone graft material preparation:* The bone graft material consisted of a 1:1 mixture of autologous bone material and anorganic bovine bone mineral (Bio-Oss, Geistlich). The quantity of autologous bone was drawn from the filter of the surgical aspirator, which was used only in the implant site. In four cases, the anatomy of the implant site required an advanced

surgery with reinforced membrane and an autologous bone graft. In these cases, a bone draw using drills in the angle of the mandible from the vestibular and distal position on the second molar was necessary. The bone drawn was then reduced into small particles with an appropriate mechanical device (Quetin).

4. *Sinus floor fracture:* In all cases, a small quantity of bone graft material was inserted, and slight compressions were performed on the osteotomes of increasing diameter. Subsequently, the sinus floor fracture was carried out by inserting the last osteotome used for the preparation of the implant site and performing one more compression (Fig 7). In this way, the presence of the graft not only

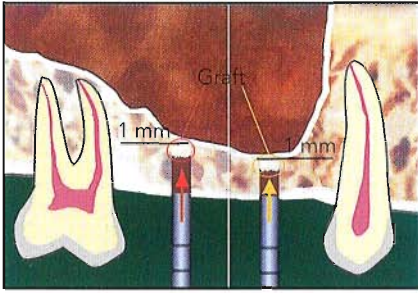


Fig 7 (left) The sinus floor is fractured after placing the graft material.

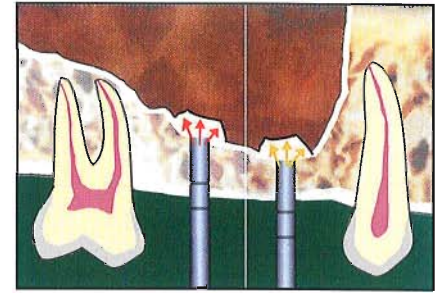
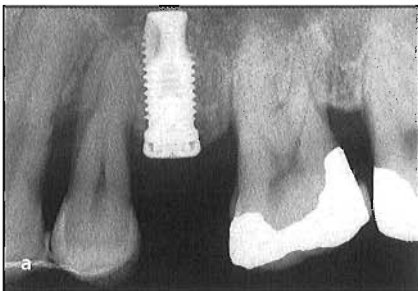
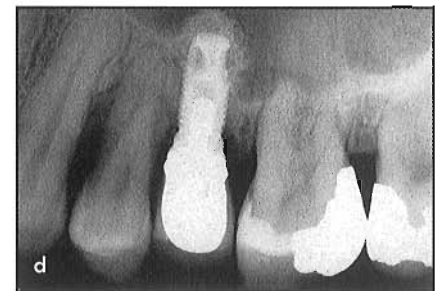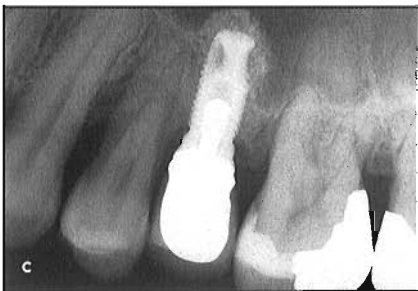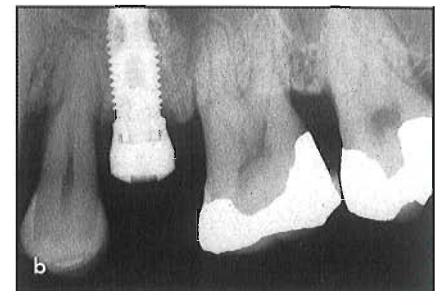


Fig 8 (right) Additional graft material is placed inside the surgical site until the desired elevation is reached.



Figs 9a to 9d Intraoral radiographs of a Brånemark 10 × 4 mm MKII implant placed using the simplified osteotome technique: (a) immediately after placement; (b) during the second surgery; (c) during the final cementation procedure (16 months after placement); and (d) 5 years after placement.



prevented direct contact between the instruments and the membrane, but also worked as a shock absorber. Next, all patients performed the Valsalva maneuver, which is considered as a predictive positive sign of microlacerations.

5. *Sinus augmentation:* Subsequent additions of bone graft material were compressed with osteotomes to achieve the desired augmentation (Fig 8). At every stage, the Valsalva maneuver was performed.

6. *Implant positioning:* All implants were placed using a diagnostic waxing-based surgical stent. The primary stability was then measured indirectly with the Osseocare device (Nobel Biocare), and the surgical site was sutured using 5-0/6-0 poly(tetra fluoro-ethylene) thread (Gore-Tex). At the end of the surgery, an intraoral radiograph was taken using the paralleling technique to verify the success of the procedure (Fig 9a).

Postoperative treatment

Pharmacologic treatment with Aulin (100 mg 12 hours after surgery and as needed thereafter depending on the symptoms) and Amoxicilline EG (1 g/day for 7 days per os) was used. The sutures were removed after 10 days. The second surgery was performed 6 to 9 months after implant placement, and an intraoral radiograph was taken (Fig 9b). After 30 to 45 days, another intraoral radiograph was taken,

Table 2 Characteristics and success rates of implants placed using the simplified osteotome technique

No. of patients	26
No. of implants	39
Implant length (n)	10 mm (34) 11.5 mm (2) 13 mm (2) 15 mm (1)
Implant diameter (mm)	4 mm (25) 5 mm (14)
Bone quality (n)	Type II/III (19) Type IV (18)
Primary stability (n)	20 N (5) 30 N (8) 50 N (26)
Loading time (mean)	5–74 mo (35.2)
Complications (n)	Mucositis (1)
No. of failures	1 (2.6%)
No. of successes	28 (97.4%)

and an impression of the implant head was made to prepare the fixed cemented provisional prosthesis, which was maintained for 3 to 6 months. Intraoral radiographs were taken once the prosthesis was cemented (Fig 9c), after 1 year (Fig 9d), and annually thereafter. The success rate was assessed according to Albrektsson's criteria (Table 2). All patients underwent a supportive periodontal therapy program with 3-month recalls.

Results

Twenty-six patients (2 men and 24 women) were treated consecutively.

Thirty-nine Brånemark implants were placed: 15 standard machined, 3 MKII machined, 5 MKIV machined, and 16 MKIV TiUnite. The length of the implants ranged from 10 to 15 mm, with an average of 10.4 mm. Implant diameter ranged from 4 to 5 mm. During the first surgery, bone quantity and bone quality were subjectively measured using radiographs and clinical data. Primary stability was quantified with the Osseocare device and ranged from 20 to 50 N.

From the time of the prosthesis insertion until the last control, the loading period varied from 5 to 74 months, with an average of 35.2 months. In one case, a particulate bone graft was necessary to reduce a slight buccal dehis-

cence, while in three other cases, the dehiscence was more evident and guided bone regeneration with bone grafting was performed. All other patients underwent only the sinus augmentation. Postoperative complications, such as nose bleeding or sinusitis, were not recorded. In one case, mucositis occurred 2 weeks after the second surgery and was treated with nonsurgical therapy. Thirty-eight of 39 implants satisfied Albrektsson's criteria at every control, achieving a success rate of 97.4%. The only failure was recorded during the second surgery, resulting from the nonintegration of the implant, which was positioned in a site with type IV bone quality (Table 2).

Discussion

The sinus augmentation technique with osteotomes created by Summers¹⁰⁻¹³ and its further variations¹⁴⁻²⁴ are acknowledged in the literature as predictably successful. The technique described in this study has several points in common with the original technique, although important differences do exist:

- In all cases, implant site preparation is completed to 2 mm less than the diameter of the implant used. This underpreparation ensures increasing lateral pressure of the implant on the site because of the typical elasticity of the maxillary bone tissue. This leads to excellent primary stability.
 - The point of the osteotomes always penetrates the previous level of the sinus floor, thus obtaining excellent and complete preparation of the implant site. In the original technique, the author suggested that the penetration of the osteotomes should never exceed 1 mm apical to the previous position of the sinus floor.
- It is worth emphasizing that the patients' vertical dimension of the residual crest was never less than 5 mm. This bone quantity is the limit required to obtain good primary stability according to Summers,¹⁰⁻¹³ Bruschi et al,¹⁴ Deporter et al,¹⁵ Cavicchia et al,¹⁹ and Rosen et al.²² Moreover, the dimensions of the elevation always guaranteed an implant length of at least 10 mm. Although some authors^{15,18,19} have focused on the importance of using rough- or porous-surfaced implants to increase stability, machined implants were used at the initial stage in this study, resulting in good primary stability and high success rates. The overall success may depend on factors such as a recovery period of at least 6 months and the underpreparation of the implant site as described earlier. Furthermore, this technique was performed in clinical situations where the
- In cases of type IV bone quality, rotating instruments are used only to create a socket, while in cases of types II or III bone quality, these instruments are used to reach the working depth before using the osteotomes. A faster and more comfortable site preparation can be obtained using drills, which is not always achievable with the original technique. In this way, the patient does not undergo repeated compressions.

elevations were limited to 5 to 6 mm with simultaneous placement limited to 1 to 2 contiguous implants. This reduced excessive pressure on the sinus membrane, avoiding consequent lacerations.

The only implant failure was recorded in a site with insufficient bone quantity (5 mm) and type IV bone quality. The failed implant was a self-tapered MKII implant with an "aggressive" surface. Further, this implant was placed in the first patient treated by the surgeon, who despite being an expert in implant therapy, was still at the beginning of the learning process with this advanced technique. However, the failure of the implant was recorded exclusively in terms of mobility during the second surgery, without any suppurative phenomena or infective complications of the maxillary sinus.

Conclusions

These preliminary data, together with the absence of complications, suggest that the simplified osteotome technique can be considered as effective and safe, although long-term, multi-center studies with a larger sample size are needed.

References

1. Esposito M, Hirsch JM, Lekholm U, Thomsen P. Biological factors contributing to failures of osseointegrated oral implants (1). Success criteria and epidemiology. *Eur J Oral Sci* 1998;106:527–551.
2. Esposito M, Hirsch JM, Lekholm U, Thomsen P. Biological factors contributing to failures of osseointegrated oral implants (2). Etiopathogenesis. *Eur J Oral Sci* 1998;106:721–764.
3. Lindh T, Gunne J, Tillberg A, Molin M. A meta-analysis of implants in partial edentulism. *Clin Oral Implants Res* 1998;9:80–90.
4. Truhlar RS, Lauciello F, Morris HF, Ochi S. The influence of bone quality on Periotest values of endosseous dental implants at stage II surgery. *J Oral Maxillofac Surg* 1997;55(12 Suppl 5):55–61.
5. Lekholm U, Zarb GA. Patient selection and preparation. In: Brånemark P-I, Zarb GA, Albrektsson T (eds). *Tissue-Integrated Prostheses: Osseointegration in Clinical Dentistry*. Chicago: Quintessence, 1985:199–209.
6. Bergh van den JPA, Bruggenkate CM, Disch FJM, Tuinzing DB. Anatomical aspects of sinus floor elevations. *Clin Oral Implants Res* 2000;11:256–265.
7. Uchida Y, Goto M, Katsuki T, Akiyoshi T. A cadaveric study of maxillary sinus size as an aid in bone grafting of the maxillary sinus floor. *J Oral Maxillofac Surg* 1998;56:1158–1163.
8. Ulm CW, Solar P, Krennmair G, Matejka M, Watzek G. Incidence and suggested surgical management of septa in sinus lift procedures. *Int J Oral Maxillofac Implants* 1995;10:462–465.
9. Tatum H. Maxillary and sinus implant reconstructions. *Dent Clin North Am* 1986;30:207–229.
10. Summers RB. A new concept in maxillary implant surgery: The osteotome technique. *Compend Contin Educ Dent* 1994;15:152–160.

11. Summers RB. The osteotome technique: Part 2—The ridge expansion technique. *Compend Contin Educ Dent* 1994;15:422–436.
12. Summers RB. The osteotome technique: Part 3—Less invasive methods of elevating the sinus floor. *Compend Contin Educ Dent* 1994;15:698–708.
13. Summers RB. The osteotome technique: Part 4—Future site development. *Compend Contin Educ Dent* 1995;16:1090–1099.
14. Bruschi GB, Scipioni A, Calesini G, Bruschi E. Localized management of sinus floor with simultaneous implant placement: A clinical report. *Int J Oral Maxillofac Implants* 1998;13:219–226.
15. Deporter D, Todescan R, Caudry S. Simplifying management of the posterior maxilla using short, porous-surfaced dental implants and simultaneous indirect sinus elevation. *Int J Periodontics Restorative Dent* 2000;20:477–485.
16. Fugazzotto PA. The modified trephine/osteotome sinus augmentation technique: Technical considerations and discussion of indications. *Implant Dent* 2001;10:259–264.
17. Cordioli GP. La procedura chirurgica per l'elevazione del seno mascellare secondo la tecnica degli osteotomi. Sinus lift consensus conference. Montecatini Terme 2001:25–27.
18. Davarpanah M, Martinez H, Tecucianu JF, Hage G, Lazzara R. The modified osteotome technique. *Int J Periodontics Restorative Dent* 2001;21:599–607.
19. Cavicchia F, Bravi F, Petrelli G. Localized augmentation of the maxillary sinus floor through a coronal approach for the placement of implants. *Int J Periodontics Restorative Dent* 2001;21:475–485.
20. Nkenke E, Schlegel A, Schultze-Mosgau S, Neukam FW, Wiltfang J. The endoscopically controlled osteotome sinus floor elevation: A preliminary prospective study. *Int J Oral Maxillofac Implants* 2002;17:557–566.
21. Toffler M. Osteotome-mediated sinus floor elevation: A clinical report. *Int J Oral Maxillofac Implants* 2004;19:266–273.
22. Rosen PS, Summers R, Mellado JR, et al. The bone-added osteotome sinus elevation technique: Multicenter retrospective report of consecutively treated patients. *Int J Oral Maxillofac Implants* 1999;14:853–858.
23. Fugazzotto PA. Sinus floor augmentation at the time of maxillary molar extraction: Technique and report of preliminary results. *Int J Oral Maxillofac Implants* 1999;14:536–542.
24. Cosci F, Luccioli M. A new sinus lift technique in conjunction with placement of 265 implants: A 6-year retrospective study. *Implant Dent* 2000;9:363–368.